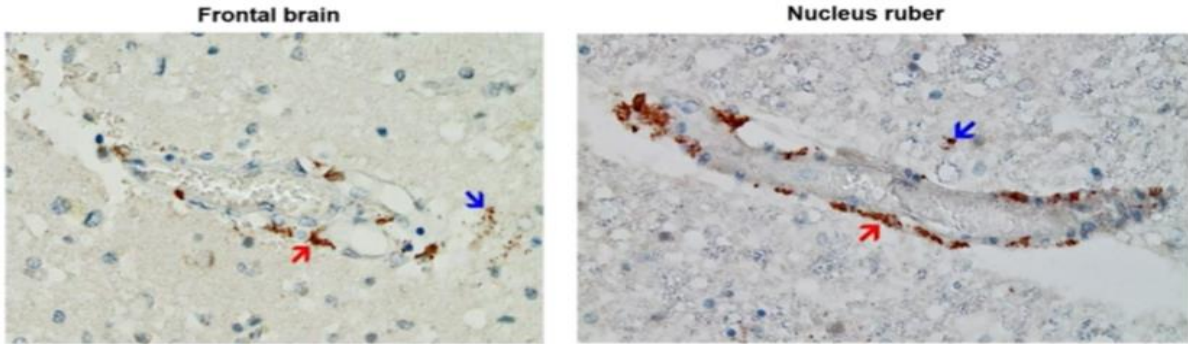


APPENDIX IV: PATHOLOGY

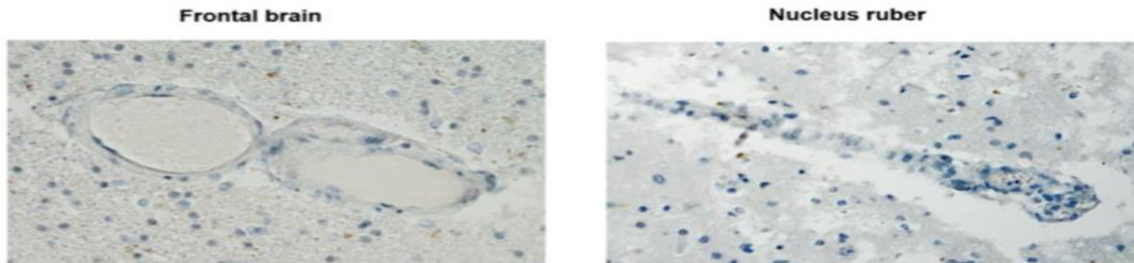
BRAIN: WITH SPIKE PROTIEN Multifocal necrotizing encephalitis [Morz, 2022]

Spike proteins in capillaries of the brain

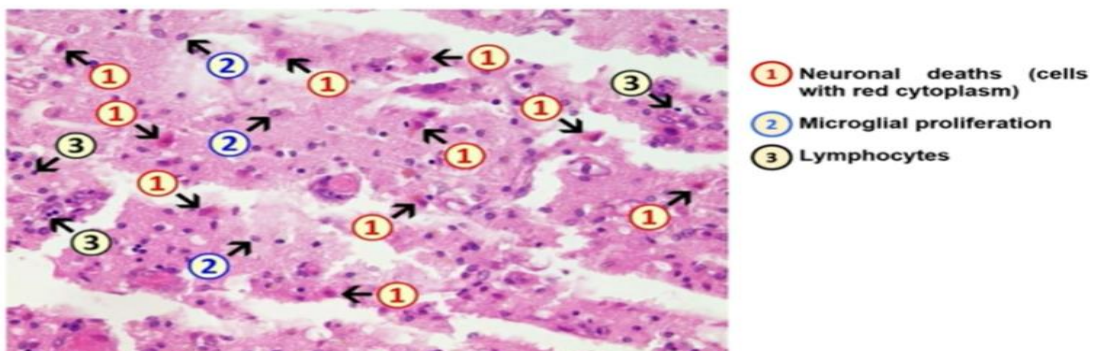


Red arrow: Endothelial cells (example)
Blue arrow: Microglial cells

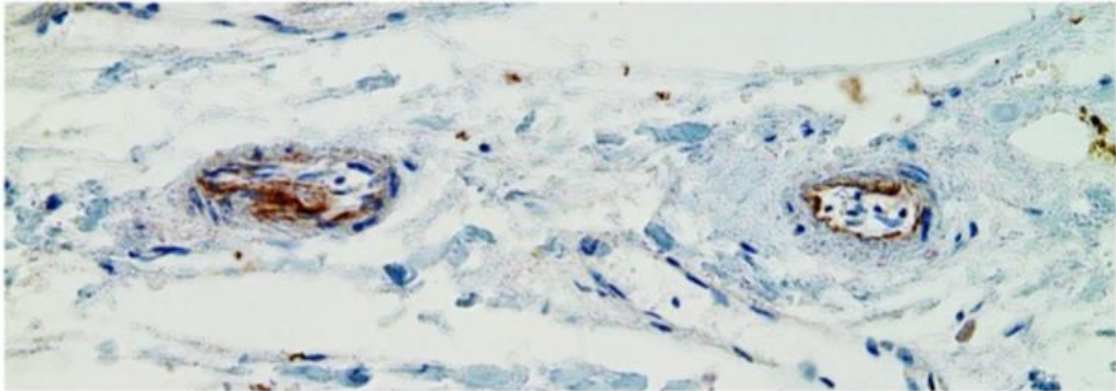
No virus nucleocapsid in the same capillaries



Damage in the frontal brain



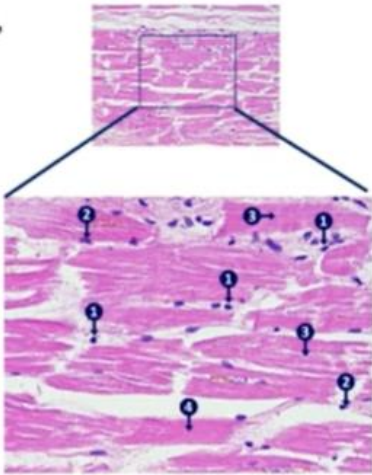
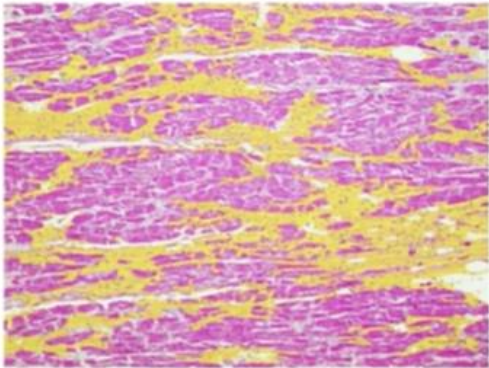
Spike proteins in the small vessels of the Myocardium



Staining Spike protein, 200x

Damage of the Myocardium

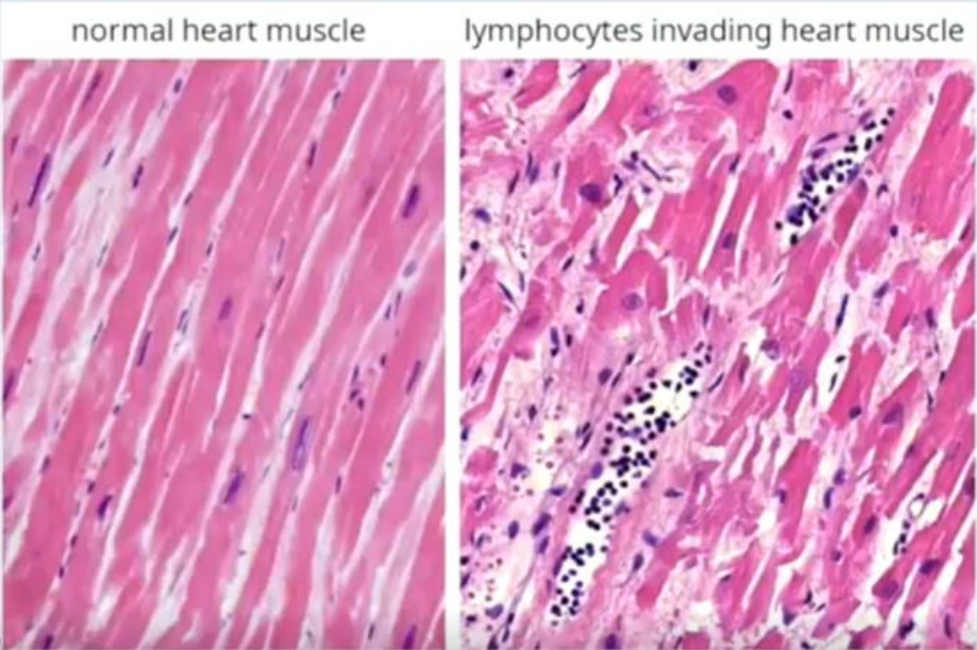
Myocardium with unusually extensive fibrosis, digitally highlighted in yellow



- 1 Lymphocytes
- 2 Histiocytes
- 3 Z-band damage
- 4 Dying Cardiomyocyte (loss of nucleus and red cytoplasm)

MYOCARDIUM WITH SPIKE PROTIEN

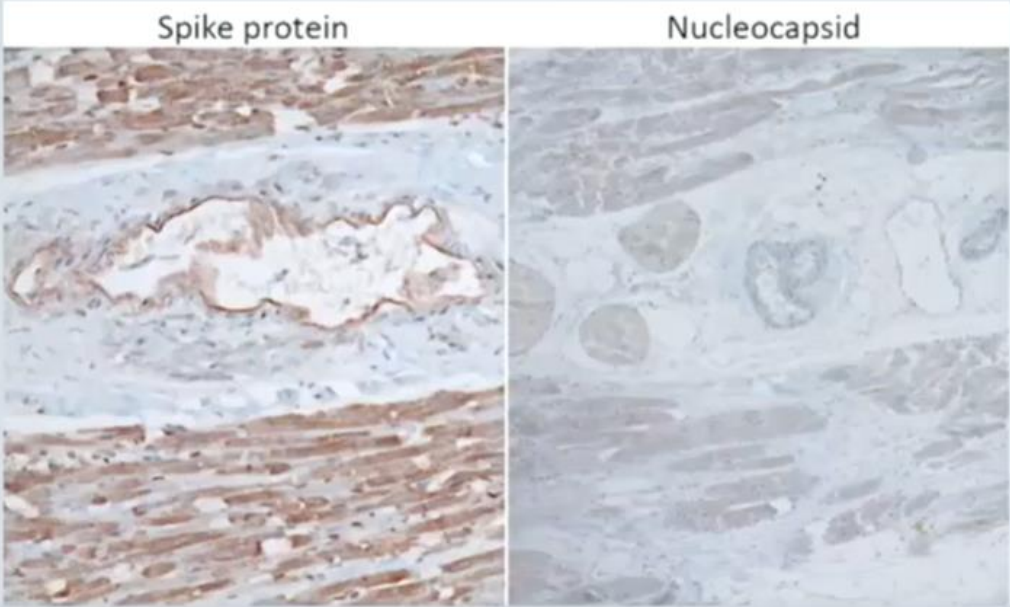
Lymphocytes invading heart muscle tissue (case 20)



© Arne Burkhardt an

53

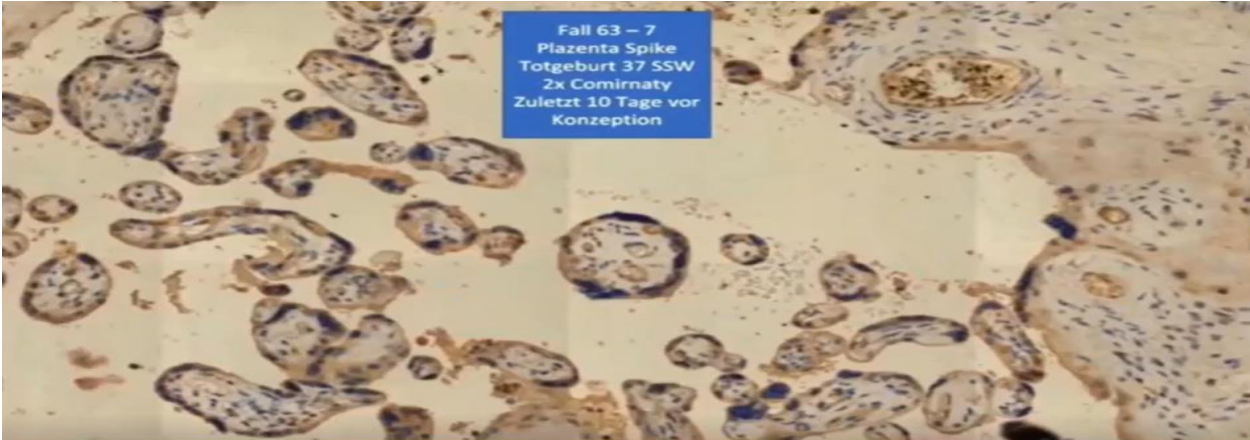
Spike protein vs. nucleocapsid expression in heart muscle (immunohistochemistry)



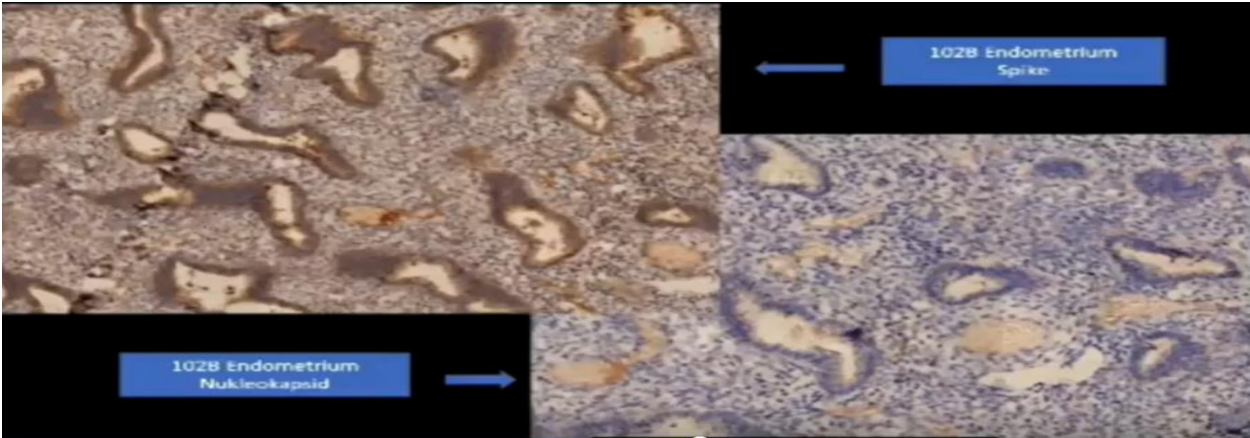
© Arne Burkhardt and colleagues 2022

54

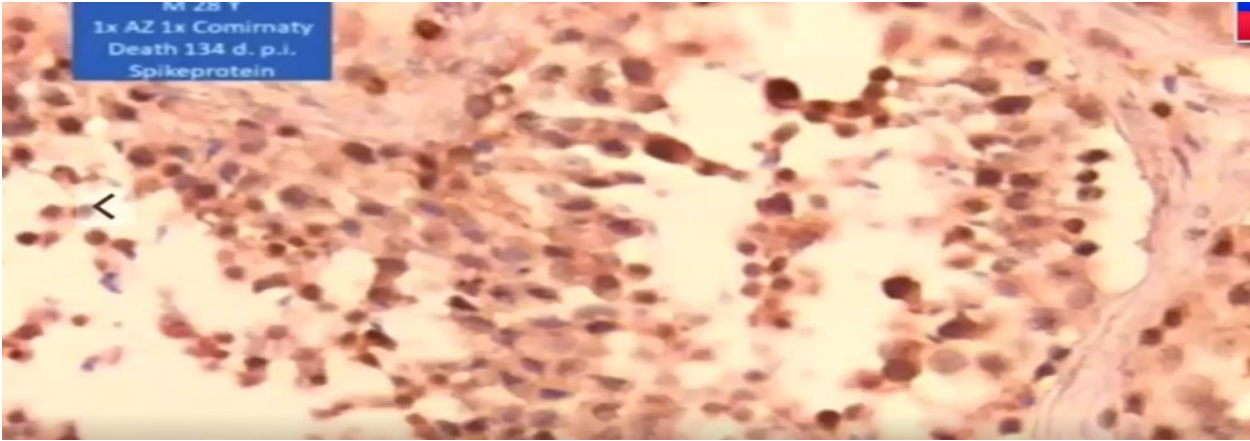
PLACENTA WITH SPIKE PROTIEN



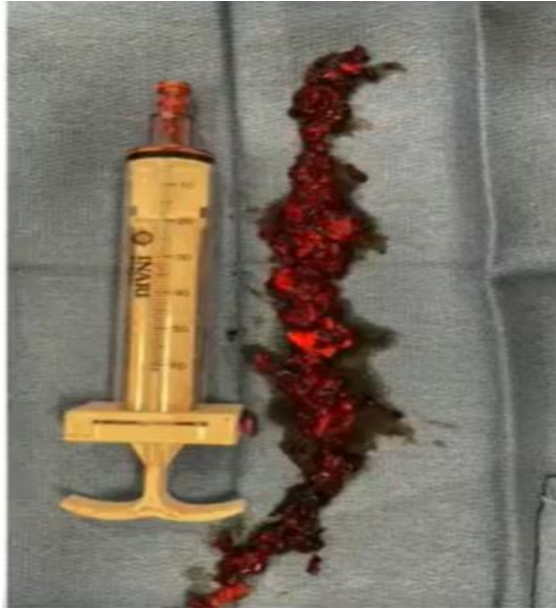ENDOMETRIUM WITH SPIKE PROTIEN



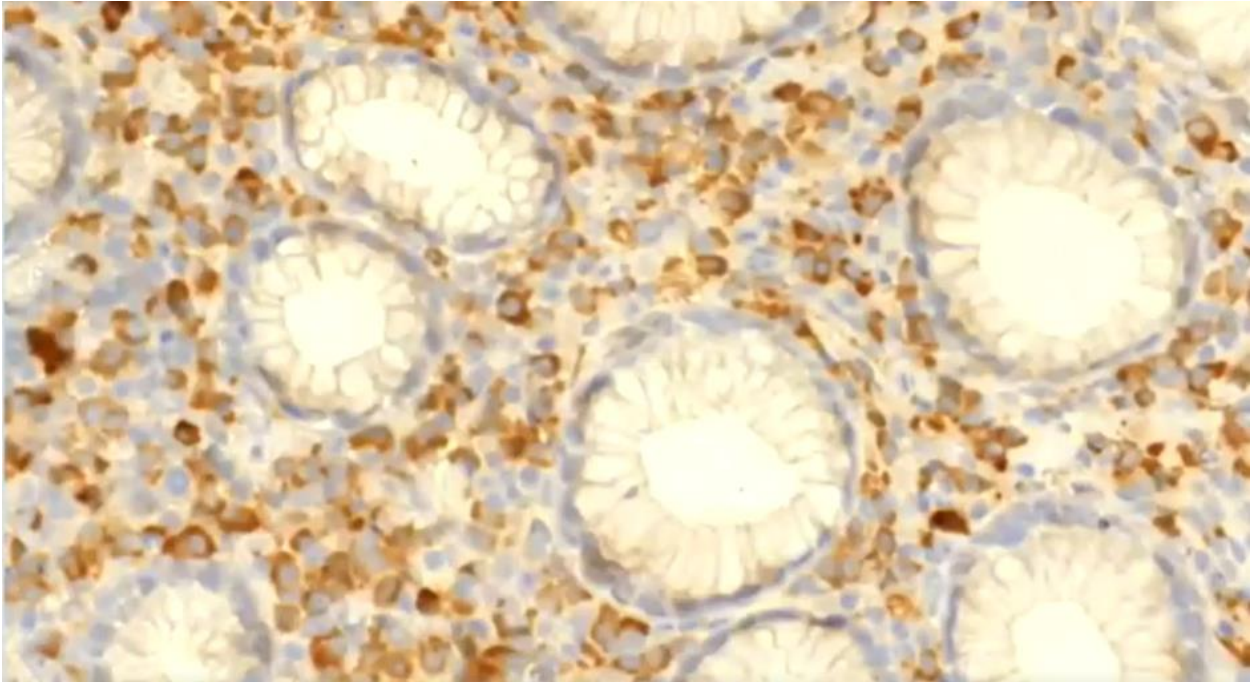
TESTIS WITH SPIKE PROTIEN



VACCINE INDUCED BLOOD CLOTS



CANCER OF STOMACH WITH SPIKE



REFERENCE FOR ABOVE SLIDES: [Cole, 2023], [Campbell, 2023], [Burkhardt, 2022].